



SAMPLE COLONOSCOPY REPORT

PATIENT NAME	PATIENT ID	DOB	AGE	SEX	EXAM DATE	PHYSICIAN	REFERRAL
Joseph R Smith	JOSSMI000	2/16/1955	60	M	01-05-2016	John W. Hart, M.D.	Keith Johnson, M.D.

TIME Start: 10:23:36 AM Reached: 11 (Mins)
End: 10:42:59 AM Withdrawal: 8 (Mins)

INDICATION : Patient with altered bowel habit with intermittent constipation with low abdominal pain.
Encounter for screening for malignant neoplasm of colon - Z12.11

CONSENT : Informed consent was obtained from the patient after providing any opportunity for questions.

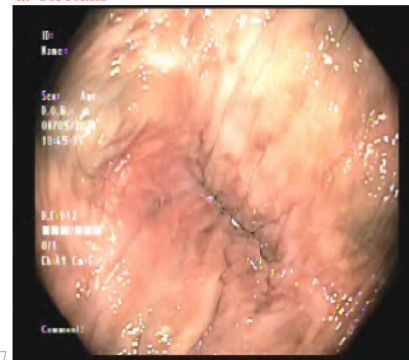
PREPARATION : EKG pulse, blood pressure and oxygen saturation monitored. Bowel preparation was given. Patient has no bleeding tendency. Has not used ASA or anticoagulation drugs for the last 5 days.

INSTRUMENT : Olympus CFQ160 SN#: 2405565

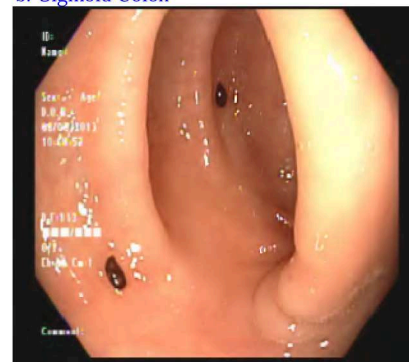
ANESTHESIA : As per anesthesia

PROCEDURE : After placing the patient in the left lateral decubitus position, the colonoscope was gently inserted into the rectum and under direct visualization advanced to the Cecum which was identified by transillumination in the right lower quadrant, identification of the ileum, appendiceal orifice, cecal strap. Color, texture, mucosa and anatomy of the colon were carefully examined with the scope. The patient tolerated the procedure well and there were no complications. After completion of the examination, patient was transferred to the recovery room.

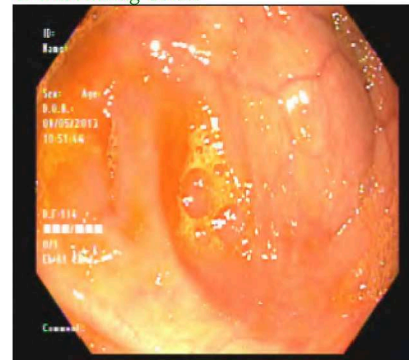
a. Rectum



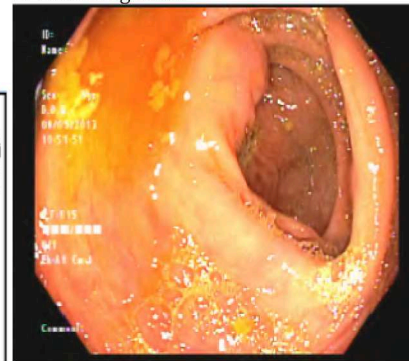
b. Sigmoid Colon



c. Descending Colon



d. Ascending Colon



FINDINGS

- Anal Canal** - Anoscopy performed showed moderate hemorrhoids
- Rectum** - Ulcerative colitis, unspecified, without complications
Mild rectal colitis. Biopsy obtained
Flat Polyp of size 0.4 cm. Polypectomy done using biopsy forceps
Sessile Polyp of size 0.6 cm. Polypectomy done using biopsy forceps
- Sigmoid Colon** - Normal mucosa
- Descending Colon** - Normal
- Splenic Flexure** - Normal
- Transverse Colon** - Normal
- Hepatic Flexure** - Normal
- Ascending Colon** - Normal
- Cecum** - Normal
- Ileocecal Valve** - Normal
- Ileum** - Not Seen

IMPRESSION : Second degree hemorrhoids - K64.1
Ulcerative colitis, unsp, w/o complications - K51.90
Rectal polyp - K62.1

PLAN : High fiber diet
Wait for pathology report
Repeat colonoscopy after 3-5 years for routine colorectal CA screening
Sitz bath. Lidocaine ointment PR
Canasa supp 1000 mg PR QHS PRN
Colace 100 mg TID
Hemorrhoid treatment with IRC to be scheduled

CPT CODES : 45385 - Colonoscopy with polypectomy

This report has been reviewed by attending physician

Electronic Signature: *John Hart, MD*

'Date: 1/6/2016 11:25:13 AM'

John W. Hart, M.D.

