

SAMPLE COLONOSCOPY REPORT

PATIENT NAME	PATIENT ID	DOB	AGE	SEX	EXAM DATE	ATTENDING PHY	REFERRAL
James Smith	3563	06/08/1941	68	M	08/21/2009	Pradeep Bansal, M.D.	John Williams, M.D.

ASST/NURSE : Jane Smith, R.N.

INDICATION : Blood in Stool - 578.1
Family Hx of Colon cancer - V16.0

CONSENT : Informed consent was obtained from the patient after providing opportunity for questions.

PREPARATION : EKG pulse, blood pressure and oxygen saturation monitored.

INSTRUMENT : CF H180AL SN#: 2807440

ANESTHESIA PROVIDER: Robert Smith, M.D.

ANESTHESIA : As per anesthesia

PROCEDURE : After placing the patient in the left lateral decubitus position, the colonoscope was gently inserted into the rectum and under direct visualization advanced to the cecum which was identified by transillumination in the right lower quadrant, identification of the ileum, appendiceal orifice, cecal strap. Color, texture, mucosa and anatomy of the colon were carefully examined with the scope. The patient tolerated the procedure well and there were no complications. After completion of the examination, patient was transferred to the recovery room.

FINDINGS

Anal Canal - External hemorrhoids

Rectum - Internal Hemorrhoids

Sigmoid Colon - Normal

Descending Colon - Normal

Splenic Flexure - Normal

Transverse Colon - Normal

Hepatic Flexure - Normal

Ascending Colon - Normal

Ileocecal Valve - Normal

Cecum - Normal

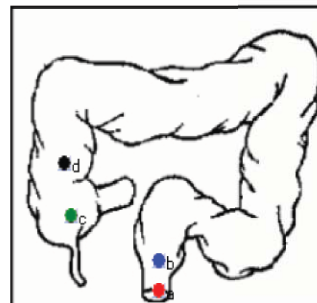
Ileum - Normal

IMPRESSION : External Hemorrhoids - 455.3
Internal Hemorrhoids - 455.0

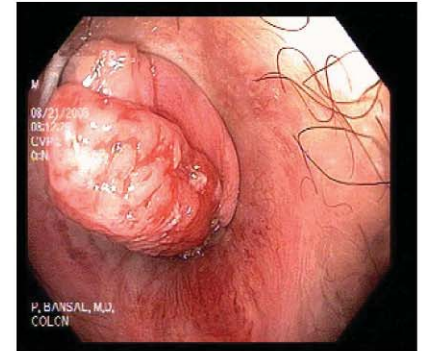
PLAN : High fiber diet
Symptomatic treatment for hemorrhoids as indicated, or consider surgical referral.

CPT CODES : 46600 - Anoscopy, diagnostic
45378 - Colonoscopy, diagnostic

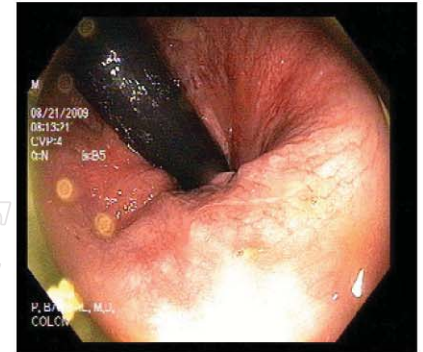
Signature : _____
Pradeep Bansal, M.D.



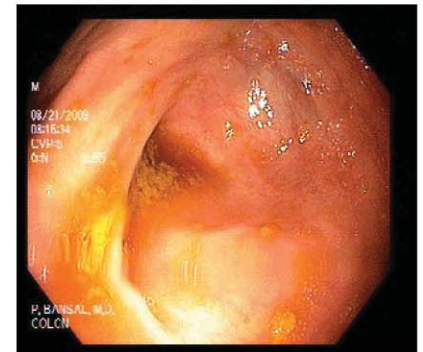a. Anal Canal



b. Rectum



c. Cecum



d. Ascending Colon

