



SAMPLE ESOPHAGOGASTRODUODENOSCOPY REPORT

PATIENT NAME	PATIENT ID	DOB	AGE	SEX	EXAM DATE	PHYSICIAN	REFERRAL
Amy W Armstrong	AMYARM000	6/25/1968	47	F	01-05-2016	John W. Hart, M.D.	Keith Johnson, M.D.

INDICATION : Functional dyspepsia - K30
Abnormal findings on diagnostic imaging of other parts of digestive tract - R93.3
Dysphagia, although currently resolved on PPI and also s/p balloon dilation of a Schatzki's ring to 20 mm about 4 months ago - R13.10

CONSENT : Informed consent was obtained from the patient after providing any opportunity for questions.

PREPARATION : EKG pulse, blood pressure and oxygen saturation monitored.

INSTRUMENT : Olympus GIFH180 SN# 2909885

ANESTHESIA : As per anesthesia

PROCEDURE : Appropriate time-out protocol was followed: the correct patient, the correct procedure and the correct equipment in the room were confirmed. The Gastroscope was gently passed through the incisoral orifice into the oral cavity and under direct visualization the esophagus was intubated. The endoscope was passed down the esophagus, through the stomach and into the 2nd Portion. Color, texture, mucosa and anatomy of esophagus, stomach and duodenum were carefully examined with the scope. The patient tolerated the procedure well and there were no complications. After completion of the examination, patient was transferred to the recovery room.

FINDINGS

- Oropharynx** - Normal
- Esophagus** - Mild distal esophagitis
Lower : Biopsy taken for GERD symptoms
- EG-Junction** - Biopsy done r/o Barrett's esophagus.
- Cardia** - Normal
- Fundus** - Normal
- Body** - Normal
- Antrum** - Gastritis, unspecified, without bleeding
- Pylorus** - Normal
- Duodenum Bulb** - Normal
- 2nd Portion** - Normal
- 3rd Portion** - Normal

IMPRESSION : Esophagitis, unspecified - K20.9
Gastritis, unspecified, without bleeding - K29.70

PLAN : Wait for pathology report
Raise the head of bed by 30 degrees at night
Anti reflux diet
Continue present medications
Follow up in office in 2 weeks
Further recommendations pending the results of biopsies

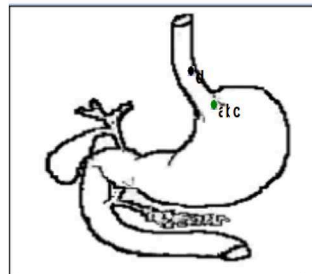
CPT CODES : 43239 - EGD with biopsy, single or multiple

This report has been reviewed by attending physician

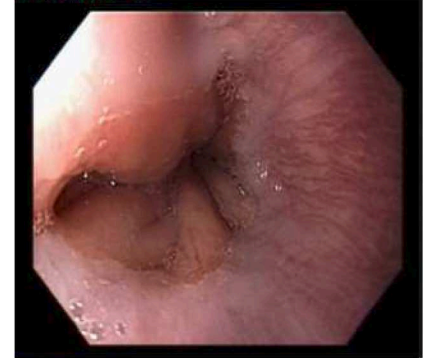Electronic Signature: 

'Date: 1/5/2016 2:38:50 PM'

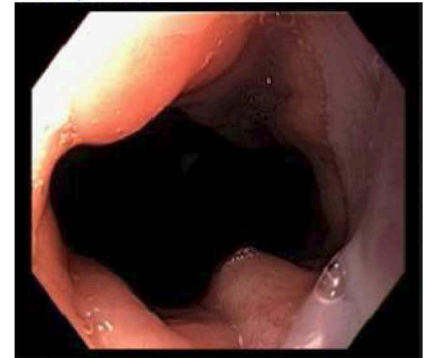John W. Hart, M.D.



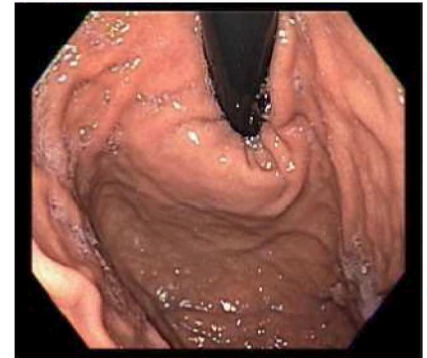
a. EG-Junction



b. EG-Junction



c. Retroflexed view



d. Mild reflux esophagitis in the distal portion

