



SAMPLE ESOPHAGOGASTRODUODENOSCOPY REPORT

PATIENT NAME	PATIENT ID	DOB	AGE	SEX	EXAM DATE	ATTENDING PHY	REFERRAL
Rose D Washington	3567	04/28/1969	40	F	08/21/2009	Pradeep Bansal, M.D.	John Williams, M.D.

ASST/NURSE : Jane Smith, R.N.

INDICATION : Anemia, rule out upper GI blood loss - 280.0
GERD - 530.81

CONSENT : Plans, risks and options were reviewed with the patient in detail. The patient understands and agrees to proceed.

PREPARATION : EKG pulse, blood pressure and oxygen saturation monitored.

INSTRUMENT : GIF H180AL SN#: 2808385

ANESTHESIA PROVIDER: Robert Smith, M.D.

ANESTHESIA : As per anesthesia

PROCEDURE : The Gastroscope was gently passed through the incisoral orifice into the oral cavity and under direct visualization the esophagus was intubated. The endoscope was passed down the esophagus, through the stomach and into the duodenum. Color, texture, mucosa and anatomy of Esophagus, Stomach and Duodenum were carefully examined with the scope. The patient tolerated the procedure well and there were no complications. After completion of the examination, patient was transferred to the recovery room.

FINDINGS

- Oropharynx** - Normal
- Esophagus** - Biopsy taken to rule out microscopic esophagitis.
- EG-Junction** - EG junction at 40 cm
- Cardia** - Normal
- Fundus** - Normal
- Body** - Normal
- Antrum** - Mild gastritis
- Pylorus** - Normal
- Duodenum Bulb** - Normal
- 2nd Portions** - Normal
- 3rd Portions** - Normal

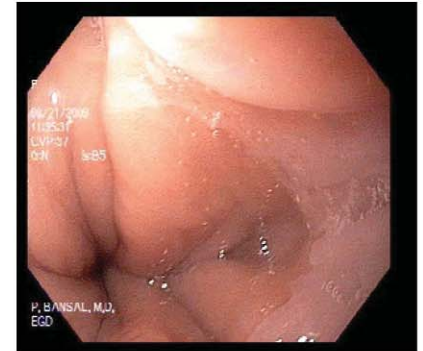
IMPRESSION : Mild gastritis - 535.40

PLAN : Wait for Pathology
Set up Colonoscopy

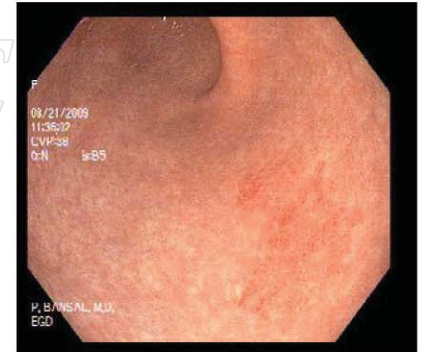CPT CODES : 43239 - EGD with biopsy
44361 - Endoscopy small bowel with biopsy

Signature : _____
Pradeep Bansal, M.D.

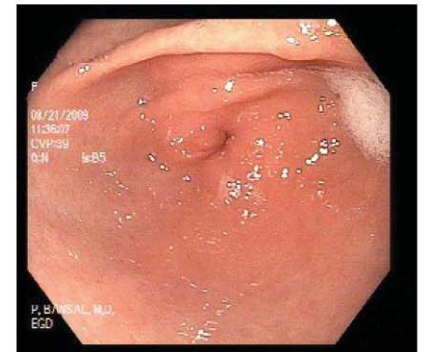
a. EG-Junction



b. Antrum



c. Antrum



d. Duodenum Bulb

